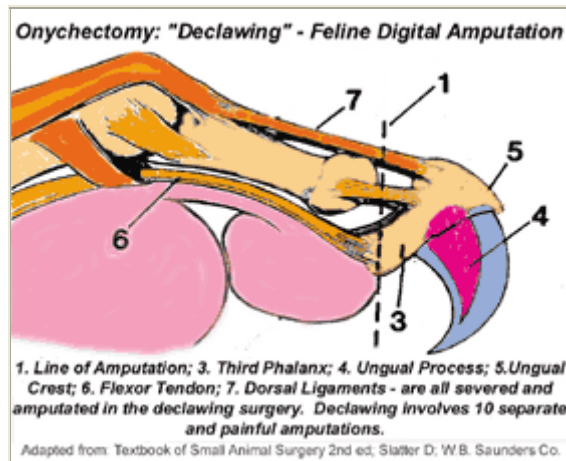

The Cat's Claws

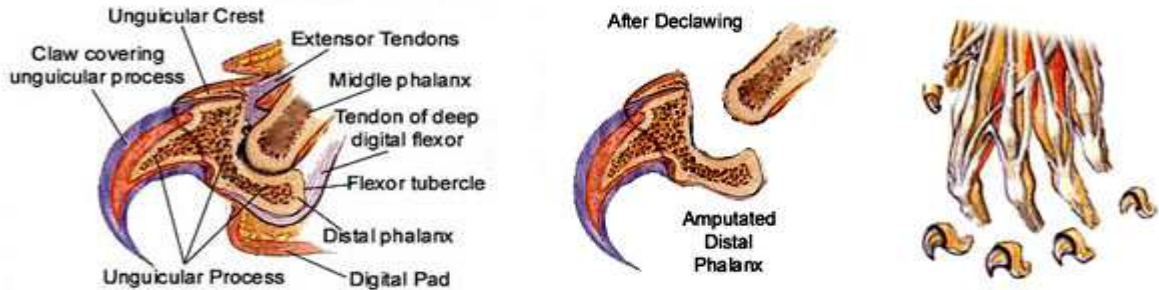
Unlike most mammals who walk on the soles of the paws or feet, cats are digitigrade, which means they walk on their toes. Their back, shoulder, paw and leg joints, muscles, tendons, ligaments and nerves are naturally designed to support and distribute the cat's weight across its toes as it walks, runs and climbs. A cat's claws are used for balance, for exercising, and for stretching the muscles in their legs, back, shoulders, and paws. They stretch these muscles by digging their claws into a surface and pulling back against their own clawhold - similar to isometric exercising for humans. This is the only way a cat can exercise, stretch and tone the muscles of its back and shoulders. The toes help the foot meet the ground at a precise angle to keep the leg, shoulder and back muscles and joints in proper alignment. Removal of the last digits of the toes drastically alters the conformation of their feet and causes the feet to meet the ground at an unnatural angle that can cause back pain similar to that in humans caused by wearing improper shoes.

Understanding Declawing (*Onychectomy*)

The anatomy of the feline claw must be understood before one can appreciate the severity of declawing. The cat's claw is not a nail as is a human fingernail, it is part of the last bone (distal phalanx) in the cat's toe. The cat's claw arises from the unguicular crest and unguicular process in the distal phalanx of the paw (see above diagram). Most of the germinal cells that produce the claw are situated in the dorsal aspect of the unguicular crest. This region must be removed completely, or regrowth of a vestigial claw and abscessation results. The only way to be sure all of the germinal cells are removed is to amputate the entire distal phalanx at the joint.

Contrary to most people's understanding, declawing consists of amputating not just the claws, but the whole phalanx (up to the joint), including bones, ligaments, and tendons! To remove the claw, the bone, nerve, joint capsule, collateral ligaments, and the extensor and flexor tendons must all be amputated. Thus declawing is not a "simple", single surgery but **10 separate**, painful amputations

of the third phalanx up to the last joint of each toe. A graphic comparison in human terms would be the cutting off of a person's finger at the last joint of each finger.



Adapted from: Atlas of Feline Anatomy for Veterinarians; Hudson/Hamilton, W.B. Saunders Company

Many vets and clinic staff deliberately misinform and mislead clients into believing that declawing removes only the claws in the hopes that clients are left with the impression that the procedure is a "minor" surgery comparable to spay/neuter procedures and certainly doesn't involve amputation (partial or complete) of the terminal-toe bone, ligaments and tendons. Some vets rationalize the above description by saying that since the claw and the third phalanx (terminal toe bone) are so firmly connected, they simply use the expression "the claw" to make it simpler for clients to "understand". Other vets are somewhat more honest and state that if they used the word "amputation", most clients would not have the surgery performed! Onychectomy in the clinical definition involves either the partial or total amputation of the terminal bone. That is the only method. What differs from vet to vet is the type of cutting tool used (guillotine-type cutter, scalpel or laser).

Onychectomy (Declawing) Surgery

The below is a clinical description of the the declawing surgery taken from a leading veterinary surgical textbbook. Contrary to misleading information, declawing is not a "minor" surgery comparable to spaying and neutering procedures, it is 10, seperate, painful amputations of the distal phalanx at the joint (*disjointing*).



Adapted from Atlas of Feline Anatomy for Veterinarians; Hudson/Hamilton, W.B. Saunders Co.

"The claw is extended by pushing up under the footpad or by grasping it with Allis tissue forceps. A scalpel blade is used to sharply dissect between the second and third phalanx over the top of the unguis crest. The distal interphalangeal joint is disarticulated (disjointed), and the deep digital flexor tendon is incised (severed). The digital footpad, is not incised. If a nail trimmer is used, the ring of the instrument is placed in the groove between the second phalanx and the unguis crest. The blade is positioned just in front of the footpad. The blade is pushed through the soft tissues over the flexor process. With the ring of the nail trimmer in position behind the unguis crest, the blade is released just slightly so that traction applied to the claw causes the flexor process to slip out and above the blade. At this point, the flexor tendon can be incised and disarticulation of the joint (disjointing) completed. Both techniques effectively remove the entire third phalanx." (Excerpted from: Slatter D; Textbook of Small Animal Surgery 2nd ed vol I, p.352 W.B. Saunders Company Philadelphia.)

Complications

Declawing is not without complication. The rate of complication is relatively high compared with other so-called routine procedures. Complications of this amputation can be excruciating pain, damage to the radial nerve, hemorrhage, bone chips that prevent healing, painful regrowth of deformed claw inside of the paw which is not visible to the eye, and chronic back and joint pain as shoulder, leg and back muscles weaken.

Other complications include postoperative hemorrhage, either immediate or following bandage removal is a fairly frequent occurrence, paw ischemia, lameness due to wound infection or footpad laceration, exposure necrosis of the second phalanx, and abscess associated with retention of portions of the third phalanx. Abscess due to regrowth must be treated by surgical removal of the remnant of the third phalanx and wound debridement. During amputation of the distal phalanx, the bone may shatter and cause what is called a *sequestrum*, which serves as a focus for infection, causing continuous drainage from the toe.

This necessitates a **second** anesthesia and surgery. Abnormal growth of severed nerve ends can also occur, causing long-term, painful sensations in the toes. Infection will occasionally occur when all precautions have been taken.

"Declawing is actually an amputation of the last joint of your cat's "toes". When you envision that, it becomes clear why declawing is not a humane act. It is a painful surgery, with a painful recovery period. And remember that during the time of recuperation from the surgery your cat would still have to use its feet to walk, jump, and scratch in its litter box regardless of the pain it is experiencing."
[Christianne Schelling, DVM](#)

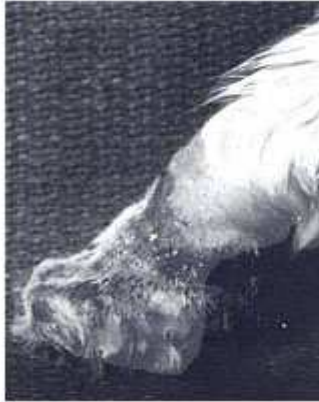"General anesthesia is used for this surgery, which always has a certain degree of risk of disability or death associated with it. Because declawing provides no medical benefits to cats, even slight risk can be considered unacceptable. In addition, the recovery from declawing can be painful and lengthy and may involve postoperative complications such as infections, hemorrhage, and nail regrowth. The latter may subject the cat to additional surgery." [The Association of Veterinarians for Animal Rights \(AVAR\)](#)

Two recent studies published in peer-reviewed veterinary journals (*Vet Surg* 1994 Jul-Aug;23(4):274-80) concluded "Fifty percent of the cats had one or more complications immediately after surgery.... 19.8% developed complications after release." Another study (*J Am Vet Med Assoc* 1998 Aug 1;213(3):370-3) comparing the complications of declawing with Tenectomy concluded "Owners should be aware of the high complication rate for both procedures." Many cats also suffer a loss of balance because they can no longer achieve a secure foothold on their amputated stumps.

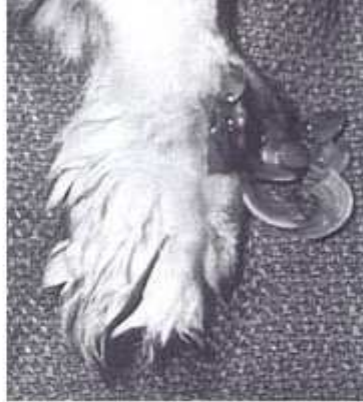Vet Surg 1994 Jul-Aug;23(4):274-80
Feline Onychectomy at a Teaching Institution: A Retrospective Study of 163 Cases.

Tobias KS
Department of Veterinary Clinical Sciences,
Washington State University, College of Veterinary Medicine,
Pullman 99164-6610.

"One hundred sixty-three cats underwent onychectomy..... Fifty percent of the cats had one or more complications immediately after surgery. Early postoperative complications included pain..., hemorrhage..., lameness..., swelling..., or non-weight-bearing..... Follow-up was available in 121 cats; 19.8% developed complications after release. Late postoperative complications included infection..., regrowth..., P2 protrusion..., palmargrade stance..., and prolonged, intermittent lameness...."



Necrosis and sloughing of soft tissue following onychectomy

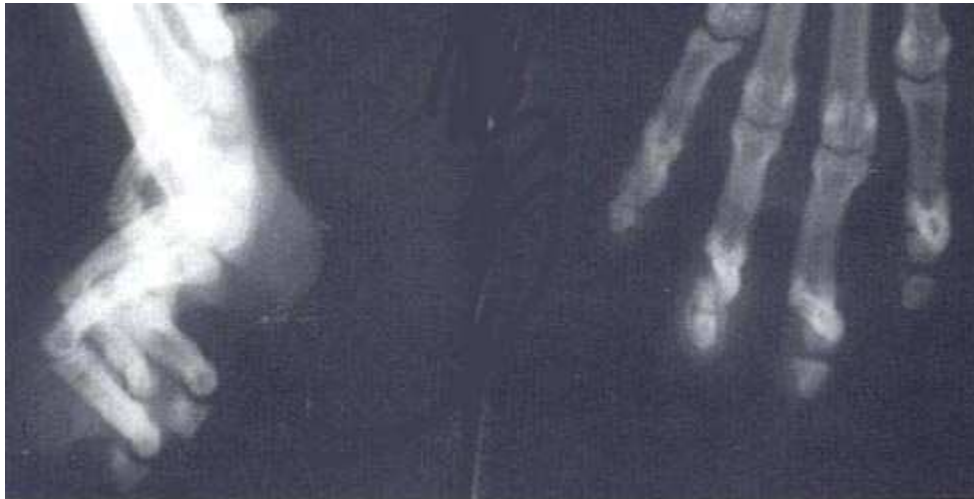


Regrowth of claws associated with inadequate amputation of the third phalanx of the first digit



Radial neuroparaxia associated with onychectomy

Photographs: Courtesy of College of Veterinary Medicine, Ohio State University



Radiographs depicting inadequate amputation of the third phalanx in a cat with regrowth of claws following onychectomy. When there is evidence of regrowth at one site, it is common to find an excessive amount of the third phalanx remaining at additional sites.

Photograph: Courtesy of College of Veterinary Medicine, Ohio State University

*J Am Vet Med Assoc 1998 Aug 1;213(3):370-3
Comparison of Effects of Elective Tenectomy or Onychectomy in Cats.*

*Jankowski AJ, Brown DC, Duval J, Gregor TP, Strine LE, Ksiazek LM, Ott AH
Department of Clinical Studies, Veterinary Teaching Hospital,
School of Veterinary Medicine, University of Pennsylvania,
Philadelphia 19104, USA.*

"Objective: *To compare short- and long-term complications after Tenectomy of the deep digital flexor tendons or onychectomy.*

Animals: *20 cats undergoing Tenectomy and 18 cats undergoing onychectomy.*

Procedure: *Cats undergoing Tenectomy or onychectomy were monitored for a minimum of 5 months to enable comparison of type and frequency of complications. Type and*

frequency of complications did not differ between procedures.

***Clinical Implications:** Owners should be aware of the high complication rate for both procedures."*

Psychological & Behavioral Complications

Some cats are so shocked by declawing that their personalities change. Cats who were lively and friendly have become withdrawn and introverted after being declawed. Others, deprived of their primary means of defense, become nervous, fearful, and/or aggressive, often resorting to their only remaining means of defense, their teeth. In some cases, when declawed cats use the litterbox after surgery, their feet are so tender they associate their new pain with the box...permanently, resulting in a life-long aversion to using the litter box. Other declawed cats that can no longer mark with their claws, they mark with urine instead resulting in inappropriate elimination problems, which in many cases, results in relinquishment of the cats to shelters and ultimately euthanasia. Many of the cats surrendered to shelters are surrendered because of behavioral problems which developed **after** the cats were declawed.

Many declawed cats become so traumatized by this painful mutilation that they end up spending their maladjusted lives perched on top of doors and refrigerators, out of reach of real and imaginary predators against whom they no longer have any adequate defense.

A cat relies on its claws as its primary means of defense. Removing the claws makes a cat feel defenseless. The constant state of stress caused by a feeling of defenselessness may make some declawed cats more prone to disease. Stress leads to a myriad of physical and psychological disorders including suppression of the immune system, cystitis and irritable bowel syndrome (IBS)..

"The consequences of declawing are often pathetic. Changes in behavior can occur. A declawed cat frequently resorts to biting when confronted with even minor threats. Biting becomes an overcompensation for the insecurity of having no claws. Bungled surgery can result in the regrowth of deformed claws or in an infection leading to gangrene. Balance is affected by the inability to grasp with their claws. Chronic physical ailments such as cystitis or skin disorders can be manifestations of a declawed cat's frustration and stress" [David E. Hammett, DVM](#)

Moral, Ethical and Humane Considerations

The veterinary justification for declawing is that the owner may otherwise dispose of the cat, perhaps cruelly. It is ethically inappropriate, in the long term, for veterinarians to submit to this form of moral blackmail from their clients.

"The Association of Veterinarians for Animal Rights is opposed to cosmetic surgeries and to those performed to correct 'vices.' Declawing generally is unacceptable because the suffering and disfigurement it causes is not offset by

any benefits to the cat. Declawing is done strictly to provide convenience for people. [The Association of Veterinarians for Animal Rights \(AVAR\)](#)

Some veterinarians have argued that some people would have their cats killed if declawing was not an option. We should not, however, allow ourselves to taken 'emotional hostage' like this. If a person really would kill her or his cat in this case, it is reasonable to question the suitability of that person as a feline guardian, especially when there are millions of non-declawed cats living in harmony with people."

Most people are vehemently opposed to declawing due to a combination of reasons: 1) because the end (owner convenience) doesn't justify the means (causing unnecessary pain to the cat); 2) because other, less harmful alternatives to declawing exist and 3) because claws are part of the nature or "catness" of cats. Overall, the view is that it is ethically inappropriate to remove parts of an animal's anatomy, thereby causing the animal pain, merely to fit the owner's lifestyle, aesthetics, or convenience without any benefit to the cat. It should be emphasized that "most people" includes virtually the entire adult population of Europe and many other countries around the world.

Many countries are particularly concerned about animal welfare and have banned declawing as abusive and causing unnecessary pain and suffering with no benefit to the cat.. One highly regarded veterinary textbook by Turner and Bateson on the biology of cat behavior concludes a short section on scratching behavior with the following statement: *"The operative removal of the claws, as is sometimes practiced to protect furniture and curtains, is an act of abuse and should be forbidden by law in all, not just a few countries."*

The following is a partial list of countries in which declawing cats is either illegal or considered extremely inhumane and only performed under extreme medical circumstances:

England - Scotland - Wales - Northern Ireland - Germany - Austria - Switzerland - Norway - Sweden

- Netherlands - Denmark - Finland - Brazil - Australia - New Zealand

[Cat Fanciers Association](#)

Declawing of Cats - CFA Guidance Statement: Approved by the CFA Board of Directors - October 1996
by Joan Miller, CFA Health Committee

"CFA's Health Committee proposed the following guidance statement on the

declawing of cats after review of the **Canadian Veterinary Medical Association's (CVMA)** position concerning declawing, and after research of scientific articles and information from the **Cornell Feline Health Center**, from Joan Miller's files of Cat Fancy and animal shelter materials and by talking with veterinarians, feline behavioral specialists, The **American Veterinary Medical Association (AVMA)**, the President of the **American College of Behaviorists and the Director of Ethical Studies** at the San Francisco SPCA. At the October 1996 meeting, the CFA Board unanimously approved this guidance statement on the declawing of cats:

CFA perceives the declawing of cats (onychectomy) and the severing of digital tendons (tendonectomy) to be elective surgical procedures which are without benefit to the cat. Because of post operative discomfort or pain, and potential future behavioral or physical effects, CFA disapproves of declawing or tendonectomy surgery."

[World Small Animal Veterinary Association](#)

Section 10-Non-therapeutic Surgical Operations on Pet Animals

- i) Surgical operations for the purpose of modifying the appearance of a pet animal for non-therapeutic purposes should be actively discouraged.*
 - ii) Where possible legislation should be enacted to prohibit the performance of non-therapeutic surgical procedures for purely cosmetic purposes, in particular;*
- d. Declawing and defanging.*
- iii) Exceptions to these prohibitions should be permitted only if a veterinarian considers that the particular surgical procedure is necessary for veterinary medical reasons."*

[The Association of Veterinarians for Animal Rights \(AVAR\)](#) position on declawing cats:

"A major concern that the AVAR has about declawing is the attitude that is evident in this situation. The cat is treated as if he or she is an inanimate object who can be modified, even to the point of surgical mutilation, to suit a person's perception of what a cat should be. It would seem more ethical and humane to accept that claws and scratching are inherent feline attributes, and to adjust one's life accordingly if a cat is desired as a companion. If this is unacceptable, then perhaps a different companion would be in order."

Dr. Nicholas Dodman, Professor of Behavioral Pharmacology and Director of the Behavior Clinic at Tufts University School of Veterinary Medicine and internationally known specialist in domestic animal behavioral research, explains declawing:

*"The inhumanity of the procedure is clearly demonstrated by the nature of cats' recovery from anesthesia following the surgery. Unlike routine recoveries, including recovery from neutering surgeries, which are fairly peaceful, declawing surgery results in cats bouncing off the walls of the recovery cage because of excruciating pain. Cats that are more stoic huddle in the corner of the recovery cage, immobilized in a state of helplessness, presumably by overwhelming pain. Declawing fits the dictionary definition of mutilation to a tee. Words such as deform, disfigure, disjoint, and dismember all apply to this surgery. Partial digital amputation is so horrible that it has been employed for torture of prisoners of war, and in veterinary medicine, the clinical procedure serves as model of severe pain for testing the efficacy of analgesic drugs. Even though analgesic drugs can be used postoperatively, they rarely are, and their effects are incomplete and transient anyway, so sooner or later the pain will emerge." (Excerpted from *The Cat Who Cried For Help*, Dodman N, Bantam Books, New York).*

Declawing robs a cat of an integral means of movement and defense. Because they cannot defend themselves adequately against attacks by other animals, declawed cats who are allowed outdoors may be at increased risk of injury or death. Scratching is a natural instinct for cats and declawing causes a significant degree of privation with respect to satisfying the instinctive impulses to climb, chase, exercise, and to mark territory by scratching. Cats simply enjoy scratching. The sensible and humane solution to undesirable scratching is to modify the cat's conduct by making changes in the environment and direct the cat's natural scratching behavior to an appropriate area (e.g., scratching post) rather than surgically altering the cat, thereby causing the animal pain, merely to fit the owner's lifestyle, aesthetics, or convenience.

The fact that many cats recover from the hideous experience of declawing without untoward effects, and even though they may not hold grudges, that doesn't seem sufficient justification for putting a family member through such a repugnant experience. In short, a declawed cat is a maimed, mutilated cat, and no excuse can justify the operation. Your cat should trust you, and depend upon you for protection. Don't betray that trust by declawing your cat.

Compliments of: Max's House & S.T.A.R.T II (Save The Animals Rescue Team)
<http://maxshouse.com>